

Laparoscopic Italian Experience with the Lap-Band®

L. Angrisani; M. Alkilani; N. Basso; N. Belvederesi; F. Campanile; F.D. Capizzi; C. D'Atri; L. Di Cosmo; S.B. Doldi; F. Favretti; P. Forestieri; F. Furbetta; F. Giacomelli; C. Giardiello; A. Iuppa; G. Lesti; M. Lucchese; F. Puglisi; L. Scipioni; M. Toppino; G.U. Turicchia; A. Veneziani; C. Docimo; V. Borrelli; M. Lorenzo

The Italian Collaborative Study Group for the Lap-Band System®, Naples, Italy

Background: An increasing number of surgeons with different levels of experience with laparoscopic surgery and open obesity surgery have started to perform laparoscopic implantation of the Lap-Band®.

Methods: An electronic patient data sheet was created and was mailed and e-mailed to all surgeons performing laparoscopic adjustable silicone gastric banding (LASGB) in Italy. Patients were recruited since January 1996. Data on 1,265 Lap-Band System® operated patients (258 M / 1,007 F; mean BMI 44.1, range 27.0-78.1; mean age 38, range 17-74 years) were collected from 23 surgeons performing this operation.

Results: Intra-operative mortality was absent. Post-operative mortality was 0.55% (7 patients) for causes not specifically related to LASGB implantation. The laparotomic conversion rate was 1.7% (22 patients). LASGB related complications occurred in 143 patients (11.3%). Pouch dilatation was diagnosed in 65 (5.2%), and 28 (2.2%) of these underwent re-operation. Band erosion was observed in 24 patients (1.9%). Port or connecting tube-port complications occurred in 54 patients (4.2%), 12 of whom required revision under general anesthesia. Follow-up was obtained at 6, 12, 18, 24, 36 and 48 months, and mean BMI was respectively 38.4, 35.1, 33.1, 30.2, 32.1 and 31.5. The percentage of patients observed at each follow-up was >60%. There was no intra-operative mortality and no complication-related mortality, with acceptable weight loss.

Conclusion: The LASGB operation is safe and effective, and deserves wider use for treatment of morbid obesity.

Key words: Morbid obesity, bariatric surgery laparoscopy, adjustable gastric banding, complications

Presented at the 17th Annual Meeting of the American Society for Bariatric Surgery, Memphis, TN, USA, June 14, 2000.

Reprint requests to: Dott. Luigi Angrisani, MD ChM, c/o LapClub – Fondazione IDIS, Via Coroglio 156, 80124 Naples, Italy. Fax: 0039/081/7623908; e-mail: lapclub.na@endosphere.it

Introduction

Laparoscopic implantation of the Lap-Band® System is the most common bariatric operation worldwide. In Italy, following introduction of the laparoscopic adjustable silicone gastric banding (LASGB) in 1993 by Favretti in Padua, an increasing number of surgeons experienced with laparoscopic and open bariatric surgery have performed this operation.^{1,2} Some surgeons have abandoned the procedure because of discouraging results in terms of complications and re-operations under general anesthesia.³ Therefore, for those surgeons currently performing the LASGB, collection and review of the results in the different centers was warranted.

Methods

A multicenter retrospective study on Lap-Band operated patients was performed. Data were collected by an electronic specifically created data sheet. Items included in the electronic sheet were discussed by a group of representatives of the most active Italian teams in this field. Very detailed patient informations (more than 150 items) were inserted in Microsoft Access (7.0). The questionnaire was mailed and e-mailed to all surgeons indicated by the local distributor (McGhan Medical S.r.l. – product BioEnterics) who have used this device. Lap-Band operated patients were recruited retrospectively from January 1996 to January

2000. LASGB was performed under general anesthesia, with the patients in lithotomy and reverse Trendelenburg (30-45°). A closed pneumoperitoneum was usually performed. All patients underwent antibiotic and antithrombotic prophylaxis. Data were expressed as mean or percentage except as otherwise indicated.

Results

Twenty-three out of 40 surgeons (57.5%) who have implanted the Lap-Band over the last 4 years sent data on 1,265 patients (258 M / 1,007 F; mean BMI 44.1, range 27.0-78.1; mean age 38, range 17-74 years). These 23 surgeons are the most active Italian teams. The remaining 17 (42.5%) have been occasional users or surgeons not currently performing the laparoscopic technique. Death during the post-operative period was reported in 7/1,265 patients (0.55%) and was not technically related to LASGB (Table 1). Causes of death were myocardial infarction (3), pulmonary embolism (3) and massive gastrointestinal bleeding (1). Laparotomic conversion was performed in 22 out of the 1,265 operations (1.7%) for difficult anatomy (9), gastric perforation (5), bleeding (4), hepatomegaly (2), splenomegaly (1), and adhesions (1) (Table 2). A median laparotomy was performed in 21 of these 22 patients.

A total of 143 out of the 1,265 patients (11.3%) developed a complication (Table 3). In this group,

Table 1: Post-operative mortality

Age Sex	BMI	Associated Disease	Post-operative Complication	Time Post-op	Cause of Death
37/M	55.2	Hypertension	No	NR	MI
61/F	53.6	Cardiomyopathy	PE	7 hrs	PE
44/M	42.4	Hypertension	PE	3 days	PE
47/F	42.1	Phlebopathy	No	NR	PE
36/F	52.4	Cardiomyopathy	No	NR	MI
38/F	47.7	Phlebopathy	No	90 days	MI
53/F*	37.1	Hypertension	Digestive Bleeding	46 days	Digestive Bleeding

MI = Myocardial infarction

PE = Pulmonary embolism

NR = Not reported

* = Laparotomic conversion due to bleeding short gastric vessels

Table 2: Laparotomic conversion in 22 patients

Reason	No.
Difficult surgical anatomy	9 (40.9%)
Gastric perforation	5 (22.8%)
Bleeding	4 (18.2%)
Hepatomegaly	2 (9.1%)
Splenomegaly	1 (4.5%)
Adhesions	1 (4.5%)

pouch dilatation was diagnosed in 65 of these 143 patients (5.2%), and 28 of these (2.2%) underwent re-operation under general anesthesia: re-banding (21), de-banding (6) and laparotomic gastric bypass (1). In 37 of these 143 patients conservative treatment with band deflation was successful. Gastric erosion alone was diagnosed in 24 of these 143 patients (1.9%). All but one patient (treated by laparoscopic band removal) were treated conservatively with band deflation. This one patient underwent laparoscopic band removal, and the remainder are under observation.

A complication of the port or connecting tube-
port system was found in 54 patients. Port dislocation was recorded in 21, and repositioning under local anesthesia was performed in 16 patients,

Table 3: Post-operative complications (143) and treatment in the 1,265 patients

Complications	Treatment	(No.)
Gastric pouch dilatation	conservative treatment	37
	re-banding	21*
	de-banding	6
	laparotomic gastric bypass	1
Gastric erosion	conservative treatment	23
	de-banding	1
Port dislocation	repositioning	16
	not reported	5
Tube/Port disconnection	re-connection	10+
	port-replacement	3
System failure	no treatment	8
	port replacement	2
System infection	conservative treatment	5
	port replacement	3
	de-banding	1+
Tube/Band disconnection	re-banding	1+
	Total no. of Complications	143

+ under general anesthesia (27.2%)

* with gastric erosion in 4 patients

while in the other 5, the procedure was not reported. In the 12 patients with tube-port disconnection (10), tube-band disconnection (1), and system infection (1), a revision under general anesthesia was required. Post-operative follow-up in terms of weight loss expressed as mean BMI is reported in Figure.1. The percentage of patients observed at each follow-up was > 60%.

Discussion

The advantage of LASGB is obvious for surgeons who routinely perform laparoscopic procedures.

In a prospective study on 277 Lap-Band® patients, O'Brien et al⁴ recorded 5 laparotomic conversions for insufficient exposure (3), bleeding (1) and insufficient tube-port length (1). The only early post-operative complication that they observed was an infection of the reservoir, which was removed. The most significant late post-operative complication in their series was pouch dilatation. Laparoscopic re-operation with stomach reduction and fixation was ineffective, and the patients were subsequently operated by open access and the band was removed from its original path and re-positioned above. No recurrence was found after this re-operation. A good weight loss was observed at 4 years.

Zimmermann and co-workers⁵ in 894 LASGB patients had one death due to acute gastric necrosis and two cases of bleeding from the subxyphoid trocar site.⁵ During follow-up 49 cases of pouch dilatation (5.5%) were observed, treated by band

change or repositioning in one or two steps. Tube-port complications were recorded in 23 patients. After 1 year of follow-up, a 40-50% weight loss was observed.

Fielding et al⁶ in a series of 335 LASGB patients recorded two early re-operations for band placement too far down the stomach creating a too large pouch. After a period of 30 days, 19 patients had complications. The most common was pouch dilatation and gastric herniation through the band (12). All these patients were re-operated, 8 by laparoscopy and 4 by laparotomy. In five patients, a tube-port infection required repositioning (3) or removal (2). Only 3 patients in their series have not obtained a sustained weight loss.

The present study is based on the experience of 23 Italian surgeons with different levels of experience in laparoscopic and bariatric surgery. Post-operative mortality was mainly due to a vascular accident (6/7) compatible with the associated disease and to the obesity itself. A 53-year-old female (Table 1) who underwent laparotomic conversion for bleeding from the short gastric vessels, was discharged from hospital on the 6th post-operative day and died of massive gastrointestinal bleeding 46 days later. Post-mortem examination revealed bleeding of the entire digestive tract without any visible source of the bleeding.

The laparotomic conversion rate in the Italian series is comparable to the conversion rate of other reported series.^{7,8} Among the causes of conversion, hepatomegaly is probably underestimated, since a number of cases with a large left liver lobe have been classified under "difficult surgical anatomy". Hepatic hypertrophy limits the view and consequently the laparoscopic access to the retrogastric passage.

Post-operative complications following Lap-Band® are usually manageable conservatively or laparoscopically. A minority have been treated by laparotomic access.

Regarding band erosions, ie. penetration of the prosthesis through the stomach wall to the gastric mucosa, two hypotheses regarding etiology are currently available: 1) technical, from seromuscular damage of the gastric wall during posterior dissection; and/or 2) functional from continuous pressure of a foreign body against the wall of a hollow organ. Both mechanisms are probably involved.⁸⁻¹⁰

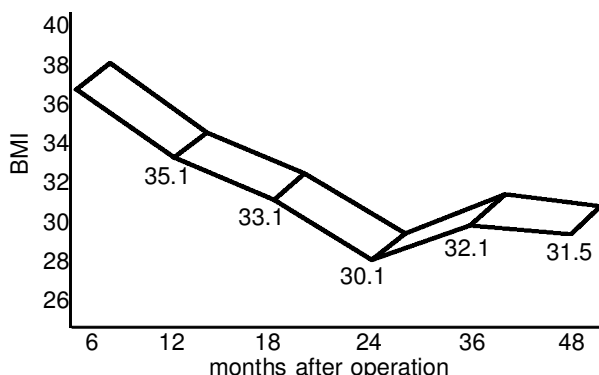


Figure 1: Post-operative mean BMI (Mean BMI at time of operation was 44.1).

This complication is largely without symptoms, and the incidence possibly depends on endoscopic follow-up. The majority of obese and ex-obese patients with a gastric band erosion in our series will likely require surgical revision at some stage.

Results of the Italian multicenter experience with low rates of mortality (0.55%), conversion (1.7%), and re-operation (6.6%) and mean BMI 31.5 at 4 years of follow-up, suggest that the Lap-Band® operation is safe and effective. In 1,265 patients, no deaths has been due to the surgical technique and/or the prosthetic material.

In the later years in this series, the Belachew tenets have become standard: a tiny “virtual” pouch, a very high retrogastric tunnel above lesser sac, and at least 4 imbricating sutures from greater to lesser curvature.¹¹ The above complications have been markedly reduced.

Conclusions

The majority of patients who undergo LASGB do well without significant complications. Study is needed in the area of pre-operative selection to identify patients who may be “under-treated” by a Lap-Band® and “over-treated” by gastric bypass or biliopancreatic diversion. Meanwhile, longer follow-up is ongoing to evaluate future maintenance of weight loss.

References

1. Favretti F, Enzi G, Pizzirani E et al. Adjustable silicone gastric banding (ASGB): the Italian experience. *Obes Surg* 1993; 3: 53-6.
2. Angrisani L, Lorenzo M, Santoro T et al. Follow up of Lap-Band complications. *Obes Surg* 1999; 9: 276-8.
3. Morino M, Toppino M, Garrone C. Disappointing results of laparoscopic adjustable silicone gastric banding. *Br J Surg* 1997; 84: 868-9.
4. O'Brien PE, Brown WA, Smith A et al. Prospective study of a laparoscopically placed gastric band in the treatment of morbid obesity. *Br J Surg* 1999; 86: 113-8.
5. Zimmerman JM, Mastroïde Ph, Michel G et al. Laparoscopic adjustable silicone gastric banding: une étude préliminaire personnelle concernant 900 cas opérés entre juillet 1995 et décembre 1998. *Eur J Coelio-Surg* 1999; 29: 25-31.
6. Fielding GA, Rhodes M, Nathanson LK. Laparoscopic gastric banding for morbid obesity: surgical outcome of 335 cases. *Surg Endosc* 1999; 13: 550-4.
7. Chelala E, Cadière GB, Favretti F et al. Conversions and complications in 185 laparoscopic adjustable silicone gastric banding cases. *Surg Endosc* 1997; 11: 268-71.
8. Dargent J. Laparoscopic adjustable gastric banding: lessons from the first 500 patients in a single institution. *Obes Surg* 1999; 9: 446-52.
9. Weiner R, Wagner D, Bockhorn H. Laparoscopic gastric banding for morbid obesity. *J Laparoendosc Adv Surg Tech* 1999; 9:23-30.
10. Elmore U, Restuccia A, Perrotta N et al. Laparoscopic adjustable silicone gastric banding (LASGB): analysis of 64 consecutive patients. *Obes Surg* 1998; 8: 399 (abstract).
11. Belachew M, Legrand M, Vincent V et al. Laparoscopic adjustable silicone gastric banding. *World J Surg* 1998; 22: 955-63.

(Received July 1, 2000; accepted November 29, 2000)