



Lap Band[®] adjustable gastric banding system

The Italian experience with 1863 patients operated on 6 years

L. Angrisani, F. Furbetta, S. B. Doldi, N. Basso, M. Lucchese, F. Giacomelli, M. Zappa, L. Di Cosmo, A. Veneziani, G. U. Turicchia, M. Alkilani, P. Forestieri, G. Lesti, F. Puglisi, M. Toppino, F. Campanile, F. D. Capizzi, C. D'Atri, L. Sciptoni, C. Giardiello, N. Di Lorenzo, S. Lacitignola, N. Belvederesi, B. Marzano, P. Bernate, A. Iuppa, V. Borrelli, M. Lorenzo

The Collaborative Study Group for the Lap Band[®] System and BIB[®]—GILB, c/o Fondazione, Institute for Spreading and Valorisation of Scientific Culture (IDIS), via Coroglio 156, 80124 Naples, Italy

Received: 13 February 2002/Accepted: 20 March 2002/Online publication: 4 December 2002

Abstract

Background: The Lap Band system procedure is currently the most common bariatric surgical procedure worldwide. This is an interim report of the experience of the 27 Italian centers participating in the national collaborative study group for Lap Band[®] (GILB).

Methods: An electronic database was specifically created. It was mailed and e-mailed to all of the surgeons now performing the laparoscopic gastric banding operation in Italy.

Results: Beginning in January 1996, 1893 patients were recruited for the study. There were 1534 women and 359 men with a mean body mass index (BMI) of (range 30.4–83.6) and a mean age of 37.8 ± 10.9 years (range; 17–74). The mortality rate has been 0.53% ($n = 10$), mainly due to cardiovascular complications (myocardial infarction, pulmonary embolism). The laparotomy conversion rate has been 3.1% (59/1893) and was higher in superobese patients (BMI > 50) than in morbidly obese patients (BMI < 50) ($p < 0.05$). Postoperative complications occurred in 193 patients (10.2%), including tube port failure ($n = 79$; 40.9%), gastric pouch dilation (GPD) ($n = 93$; 48.9%), and gastric erosion ($n = 21$, 10.8%). Most GPD (65.5%) occurred during the first 50 patients treated at each center. The incidence of GPD decreased as the surgeons acquired more experience. Surgery for complications was often performed by laparoscopic access, rarely via laparotomy. No death was recorded as a consequence of surgery to treat complications. Weight loss has been evaluated at the following intervals: 6, 12, 24, 36, 48, 60, and 72 months, with BMI 37.9, 33.7, 34.8, 34.1, 32.7, 34.8, and 32.

Conclusions: The Lap Band system procedure has a very low mortality rate and a low morbidity rate and it yields

satisfactory weight loss. Surgery for complications can be performed safely via laparoscopic access.

Key words: Morbid obesity — Laparoscopic adjustable gastric banding — Complications — LapBand system

The worldwide diffusion over the last 5 years of laparoscopic gastric banding (LGB) for the treatment of obesity has been a significant event in the field of general surgery [7]. Following laparoscopic cholecystectomy, LGB is one of the most common laparoscopic operation performed today and is now the method of choice at most bariatric surgery centers in Italy [3].

Although a growing number of patients are undergoing this type of procedure, some centers are still in their learning curve, and long-term multicenter studies on complications and follow-up are still lacking.

The goal of the Italian Collaborative Study Group for the LapBand system (GILB) is to promote a standardized method of communication among surgeons of different centers. It collects patient twice a year. It also provides quality control of the results obtained with this operation at each center. Thus, it allows a fast and continuous exchange of information, aimed at improving the short- and long-term results of LGB. This is an interim report of the experience of the 27 Italian centers participating in this national survey.

Patients and methods

A retrospective study was performed of LapBand system-operated patients treated between January 1996 and January 2002. An electronic data sheet (>150 items/patient) was specifically created (Microsoft Access 7.0, Inamed Health, 1035 Cindy Lane, Carpinteria, CA, USA). It was then mailed and e-mailed to all of the surgeons who perform this

operation in Italy, as indicated by the records of local distributor (McGhan s.r.l.; product line, BioEnterics, via Lombardia 30, Rome, Italy).

All patients were operated on under general anesthesia in lithotomy and reverse Trendelenburg (30–45°). A closed carbon dioxide pneumoperitoneum was usually created. All patients underwent antithrombotic and antibiotic prophylaxis.

The following items were considered for this study: age, sex, body mass index (BMI), intraoperative and postoperative complications with their treatment, laparotomic conversion, and mortality. Follow-up was obtained at 6, 12, 24, 36, 48, 60, and 72 months.

Data are expressed as mean \pm standard deviation (SD), except as otherwise indicated. Statistical analysis was done by means of Fisher's exact test, $p < 0.05$ was considered significant.

Results

Beginning in January 1996, 1893 patients, treated at 27 centers, were entered into the registry of the Italian Group for LapBand. There were 1534 women and 359 men with a mean BMI of 43.7 ± 6.2 (range, 30.4–83.6) and a mean age of 37.8 ± 10.9 years (range, 17–74).

Mortality

The postoperative mortality rate was 0.53% (10/1893). Preoperative cardiovascular comorbidities were present in all of these patients, including cardiomyopathy ($n = 4$), hypertension ($n = 4$), and phlebopathy ($n = 2$). Pulmonary embolism within 72 h after the surgery was the cause of death in two patients. Five patients died of myocardial infarction and one of pulmonary embolism following hospital discharge. One patient suffering from hypertension was converted intraoperatively to open surgery for bleeding from the short gastric vessels. She had an uneventful postoperative recovery but was readmitted to the hospital 46 days later and died of massive bleeding from the gastrointestinal tract. A single patient perforated her dilated gastric pouch 20 months postoperatively; she underwent a proximal gastrectomy and died of disseminated intravascular coagulation.

Laparotomic conversion

Laparotomic conversion was performed in 59/1893 patients (3.1%). The reported causes were technical difficulties ($n = 24$; 40.6%), hepatosplenomegaly ($n = 14$; 23.8%), bleeding ($n = 7$, 11.9%), gastric perforation ($n = 7$, 11.9%), and adhesions ($n = 1$; 1.7%). In six cases (10.1%), the reasons for switching to open surgery were not reported. The incidence of laparotomic conversion was significantly higher ($p < 0.05$) in superobese patients (BMI > 50) than in morbidly obese patients (BMI < 50) (14/249; 5.2% vs 35/1684; 2.1%).

Postoperative complications

Postoperative complications included gastric pouch dilation (GPD), intragastric migration (erosion), and tube port system leaks and/or rupture.

GPD was been diagnosed in 93/1893 (4.8%) patients. In 75 patients, a single episode was observed, whereas two or three episodes of pouch dilations were observed in 14 (15.2%) and four (4.3%) patients, respectively. The diagnosis was incidental in 43 cases (45.6%) and was made during routine radiographic examinations (barium meal or Gastrografin). In 50 cases, GPD was suspected on the basis of the following clinical symptoms: vomiting ($n = 28$; 56%), pyrosis ($n = 12$; 24%), regurgitation ($n = 5$; 10%) and epigastric pain ($n = 5$; 10%). Conservative treatment by band deflation was successful in 47 cases (41.3%). In 29 patients (31.5%), a reoperation under general anesthesia was performed to achieve band removal ($n = 12$) or repositioning ($n = 17$). In all but one patient submitted to band removal, the reoperation was done via a laparoscopic approach. Thirteen patients (14.1%) treated conservatively were left with a dilated gastric pouch for clinical and radiological monitoring. Treatment options and their outcome were not reported in three cases. Two patients in this series experienced perforation of a dilated gastric pouch. One of these patient is reported in the Mortality section; the other underwent total gastrectomy with esophagejejunostomy in two steps and is currently alive and well. There were 14 patients with two episodes of GPD. A band removal was performed in two cases and a repositioning in two others; conservative treatment was adopted in the remaining 10. In four patients with three GPD episodes, band removal was performed in three patients, and one received a laparotomic Roux-en-Y gastric bypass. All but the last of these cases were operated via laparoscopy. In terms of the sequential number of patients that have developed GPD, 61 of 93 cases occurred within the first 50 patients, 20 cases were recorded between patients 51 and 100, nine occurred between patients 101 and 150, and two and one case occurred between patients 151 and 200 and 201 and 250, respectively.

Intragastric migration (erosion) was diagnosed in 21 of 1893 patients (1.1%). It was treated by band removal in three cases, by laparotomy in one case, by laparoscopy in the remaining two cases. Deflation was performed in five cases. Fourteen patients are currently being followed by close clinical and endoscopic monitoring. Intervention will be scheduled as necessary on a nonurgent basis.

Tube port complications were diagnosed in 79 of 1893 patients (4.1%). Port dislocation occurred in 25 patients (31.6%), system leaks in 26 (33%), tube port disconnection in 19 (24.1%), system infection in seven (8.8%), and band perforation in two (2.5%).

Reoperation for complications of the tube port system were performed under local (32/79 patients) and general anesthesia (16/79 patients).

Weight loss

Postoperative mean BMI was 37.9, 33.7, 34.8, 34.1, 32.7, 34.8 and 32 after 6, 12, 24, 36, 48, 60, and 72 months, respectively. The percentage of patients available at each follow-up has decreased with time, remaining around

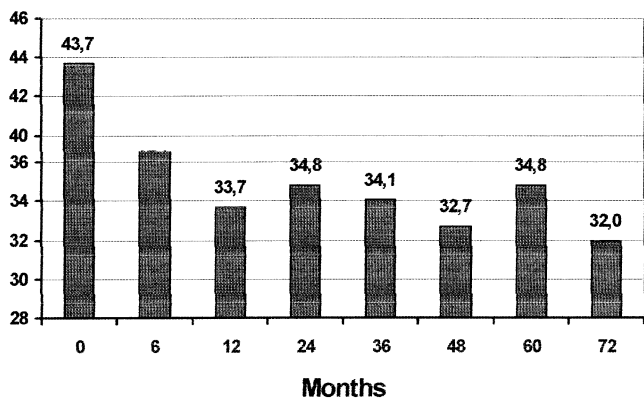


Fig. 1. Weight loss in terms of mean BMI (vertical axis) over time (horizontal axis).

70% at 5 years. Mean BMI during the years is reported in Fig. 1.

Discussion

Laparoscopic gastric banding is one of the most common bariatric operation performed worldwide. Within the last 5 years, 80,000 LapBand systems have been implanted, mostly in Europe, South America and Australia [1, 2, 6]. In Italy, this is the method of choice at the majority of obesity surgery centers [3]. The explosive popularity of this operation is due to a number of different factors. Certainly, a very important role has been played by the extraordinary coincidence of the steadily growing awareness of obesity as an evolving chronic disease, with its potentially lethal complications, and the large diffusion in general surgery of laparoscopic techniques [4, 14].

Hospital mortality with the LapBand system was reported in five of 10 postoperative deaths. Among the late deaths, one patient succumbed to untreatable sepsis and disseminated intravascular coagulation (DIC), which was directly related to pouch perforation, 18 months after banding. The mortality rate documented in this multicenter study is comparable to the experience of other single-center series reported in the international literature and is two to three times lower than that reported for other more invasive procedures—namely, gastric bypass and vertical-banded gastroplasty [2, 13, 15, 16].

The overall laparotomic conversion rate (59/1893; 3.1%) is similar that for other reported experiences, but patients with a BMI > 50 in this series were converted to open surgery more frequently ($p < 0.05$) than those with a BMI < 50 [1, 2, 9, 12]. Abdominal wall thickness, visceral and omental fat, and hepatomegaly increase the complexity of the laparoscopic procedure by limiting the access and the view to the retrogastric passage [1, 8, 9, 15]. For this reason, surgeons in the initial phase of their experience with the LapBand system procedure should avoid treating superobese patients because of the technical complexities encountered in the advanced stages of this disease. Although hepatomegaly accounted for 23.8% of the causes for laparotomic conversion, a

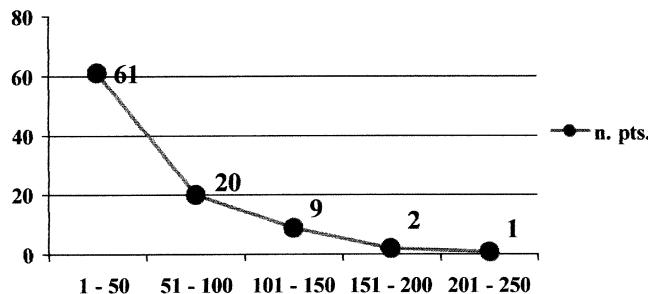


Fig. 2. Number of patients with gastric pouch dilation (vertical axis) plotted against the range of the number of patient cases treated at each center (horizontal axis) (learning curve).

number of patients with left liver lobe hypertrophy were probably included in this group.

Pouch dilation is the real Achilles heel of this operation, as it is the most common complication of laparoscopic gastric banding [1, 9, 12, 15, 16]. The high incidence of GPD in the early evolutionary phase of the surgical technique was reported in some pioneer series [5, 8, 11]. A small virtual pouch, created by passing behind the stomach above the bursa omentalis and fixing the band with three to five gastro-gastric stitches is the primary goal of the standard surgical technique. Data from the present study clearly show that the rate of this complication decreases as the surgeon's experience with this operation increases (Fig. 2). Most GPD in fact occurred in patients who were operated on during the learning curve. Better surgery, together with better patient management, will continuously reduce the rate of pouch dilation. Most of these complications can be resolved by band deflation; if surgery is needed, minimally invasive access can be used to remove or reposition the prosthesis [5, 16]. Recently, pouch necrosis and perforation have been reported by Kirchmayr et al., with the laparoscopically implanted Swedish laparoscopic adjustable band (Obtech, Zug, Switzerland) [10]. Although this patient in the Innsbruck series, like our own patient in Naples, survived this dreadful complication, another patient in the Italian series died of unbeatable sepsis. These three cases should serve to alert any surgeon dealing with this operation of the need for close monitoring and early treatment of any episode of pouch dilation.

Intragastric migration (erosion) is a rare complication of LPG [12, 15, 16]. A clear explanation of this phenomenon is not available. Perhaps a sero-muscular damage during dissection is responsible for initiating the migration process. Treatment of this complication is also controversial. Laparoscopic removal is feasible, of course, but a number of surgeon are monitoring their patients with the hope of a transoral removal via gastroscopy, which has been proved feasible but has not been as yet standardized. In any case, erosions are rare and manageable and generally do not constitute a crisis.

Tube port rupture by partial or complete fracture has been an annoying complication of the LapBand procedure that has often required revision surgery but seldom necessitates general anesthesia [2, 3, 11, 16]. Material and manufacturing improvements, combined with a careful surgical technique, have sharply reduced this

type of complication, which nowadays should be considered a historical complication of LapBand surgery.

Weight loss is the ultimate goal of surgery for the treatment of obesity. Six-year results in the present multicenter study are very good and comparable to those reported in other single-surgeon experiences [2, 12, 16]. These data certainly need to be confirmed in following years and also by other centers. Future efforts should concentrate on improving the preoperative patient selection of candidates for the Lap Band procedure and trying to identify objective criteria for the exclusion of patients with low levels of compliance for this operation.

References

1. Abu Abeid S, Szold A (1999) Results and complications laparoscopic adjustable gastric banding in an early and intermediate experience. *Obes Surg* 9: 188–190
2. Allen JW, Colerman MK, Fielding GA (2001) Lessons learned from laparoscopic gastric banding for morbid obesity. *Am J Surg* 182: 10–14
3. Angrisani L (2001) Laparoscopic Italian experience with the LapBand. *Obesity Surg Italian Group for LapBand* 11: 1307–1311
4. Angrisani L, Lorenzo M, De Palma G, Sivero L, Catanzano C, Tesauro B, Persico G (1995) A Laparoscopic cholecystectomy in obese patients compared with non-obese patients. *Surg Laparosc Endosc* 5: 197–201
5. Angrisani L, Lorenzo M, Santoro T, Nicodemi O, Da Prato D, Ciannella M, Persico G, Tesauro B (1999) Follow-up of LapBand complications. *Obes Surg* 9: 276–278
6. Belachew M (2001) First successful laparoscopic gastric band. *Obes Surg* 11: 778
7. Belachew M. (2001) Histoire de l'anneau modulable laparoscopique (LAGB) du rêve à la réalité. *Eur J Coelochir* 38: 4–10
8. Belachew M, Legrand MJ, Defechereux TH, Burtheret MP, Jaquet N (1994) Laparoscopic adjustable silicone gastric banding in the treatment of morbid obesity: a preliminary report. *Surg Endosc* 8: 1354–1356
9. Cadière GB, Bruyns J, Himpens J (1994) Laparoscopic gastroplasty for morbid obesity. *Br J Surg* 81: 1524–1527
10. Kirchmayr W, Ammann K, Aigner F, Weiss HG, Nehoda H (2001) Pouch dilatation after gastric banding causing gastric necrosis. *Obes Surg* 11: 770–772
11. Miller K, Retenbacher L, Hell E (1996) Adjustment and leak detection of the adjustable silicone gastric band (ASGB) and LapBand adjustable gastric (LAGB) band system. *Obes Surg* 6: 406–411
12. O'Brien PE, Brown WA, Smith A, McMurrick PJ, Stephens M (1999) Prospective study on a laparoscopic placed, adjustable gastric band in the treatment of morbid obesity. *Br J Surg* 86: 113–118
13. Pories WP, Swanson MS, MacDonald KG, Long SB, Morris PG, Brown BM, Bakarat HA, deRamon RA, Israel G, Dolezal JM (1995) Who would have thought it? An operation proves to be the most effective therapy for adult-onset diabetes mellitus. *Ann Surg* 222: 339–352
14. Seidell JC, Deerenberg I (1994) Obesity in Europe: prevalence and consequences for use of medical care. *Pharmacoeconomics* 5 (Suppl): 38–44
15. Weiner R, Emmerlich V, Wagner D, Bockolm H (1998) Management and therapy of postoperative complications after gastric banding for morbid obesity. *Chirurg* 66: 1082–1088
16. Zimmermann JM, Blanc M, Mashoyan P, Zimmermann E, Grimaldi JM (2001) La gastroplastie par anneau ajustable, voie coelioscopique, état de l'art. *Eur J Coeliosurg* 38: 121–132