

Treatment of Morbid Obesity and Gastroesophageal Reflux with Hiatal Hernia by Lap-Band

Luigi Angrisani, MD; Paola Iovino, MD¹; Michele Lorenzo, MD, PhD; Tito Santoro, MD; Francesco Sabbatini, MD, ChM¹; Ernesto Claar, MD¹; Ornella Nicodemi, MD; Giovanni Persico, MD, ChM; Beniamino Tesauro, MD, ChM

1st Department of Surgery and ¹Department of Gastroenterology, University Federico II, Medical School, Naples, Italy

Background: Esophageal reflux is common in obese patients. Hiatal hernia is considered a potential contraindication to placement of a Lap-Band.

Methods: Esophageal investigation in patients who were candidates for a Lap-Band included clinical evaluation of symptoms (scoring system), endoscopic and radiologic evaluation, 24-h pH test, and stationary manometry. Patients with gastroesophageal reflux (GER) with or without hiatal hernia underwent the Lap-Band procedure.

Results: GER was diagnosed in 12/40 morbidly obese patients, 11 of whom received a standard Lap-Band (3 patients were radiologically diagnosed with transient hiatal hernia). One patient with a large hiatal hernia underwent closure of the diaphragmatic esophageal hiatus, and the Lap-Band was positioned similarly to an Angelchik prosthesis. All but 1 patient who was lost at follow-up were symptom-free (range 1–24 months).

Conclusion: GER with or without hiatal hernia is not a contraindication for obese patients undergoing a Lap-Band procedure. It accomplishes by a single operation satisfactory treatment of these two disturbing diseases.

Key words: Morbid obesity, gastroesophageal reflux, laparoscopy.

Introduction

Gastroesophageal reflux (GER) is very frequent in morbidly obese patients. Hiatal hernia has been con-

sidered by some to be a contraindication to the use of a Lap-Band (McGhan Medical Srl) Lap-Band because of technical problems due to the surgical anatomy of this condition. Few data are available on obese patients with GER symptoms, positive 24-h pH test results, and lower esophageal sphincter (LES) who undergo laparoscopic banding with a virtual pouch. Technical modifications to the standard operation have been introduced in selected cases. This is a retrospective study of massively obese patients in our series who had GER with or without a hiatal hernia who were treated by placement of a Lap-Band.

Patients and Methods

Preoperative gastroesophageal investigations of patients considered for laparoscopic adjustable silicone gastric banding (LASGB) in our center include as a protocol these investigations for GER: clinical evaluation of specific symptoms, esophagogastric barium meal, esophagogastroscope, 24-h pH test, and stationary manometry.^{1,2} For this study, obese patients were considered affected by GER if specific symptoms and abnormal 24-h pH ambulatory test results were present. The esophageal symptoms score was calculated by a questionnaire dealing with the frequency and intensity of heartburn, regurgitation, and dysphagia before and after surgery.³ The frequency of symptoms was scored from 0 to 3 (0 = absent, 1 = ≤ 2 days/wk, 2 = 3–5 days/wk, 3 = 6 or 7 days/wk). The intensity of symptoms

Presented at the 3rd World Congress of the International Federation for the Surgery of Obesity, Bruges, Belgium, September 4, 1998. Reprint requests to: Luigi Angrisani, MD, Piazza Vittoria 7, I-80121 Naples, Italy. Fax: 39.81.7623908. e-mail: lapclub.na@endosphere.it

Table 1. Results of preoperative esophageal investigations

Pt.	Age/sex	R	D	H	pH ^a	Weight (kg)	
						Preoperative	Postoperative (mo follow-up)
1	44/F	1	0	2	10.3	120	95 (48)
2 ^b	50/F	0	4	4	15.1	98	81 (12)
3 ^c	52/F	1	0	0	4.9	115	94 (6)
4	28/F	2	0	2	11.5	110	91 (12)
5	28/F	2	0	5	14.6	127	84 (12)
6	22/F	0	0	5	5.4	Lost	
7	20/M	3	5	4	9.6	145	130 (6)
8	37/F	0	0	5	5.1	105	87 (6)
9 ^c	19/F	0	0	5	7.4	156	133 (6)
10 ^c	59/F	0	2	0	6	104	94 (3)
11	21/F	1	0	0	5.6	142	132 (3)
12	23/M	5	0	6	14.3	160	150 (3)

R, regurgitation score; D, dysphagia; H, heartburn

^aLES, lower esophageal sphincter.

^bPercent of total time of acid exposure in 24-h (normal value <4.45).

^cHiatal hernia.

^dSmall transient sliding hiatal hernia.

was scored from 0 to 3 (0 = absent, 1 = mild, 2 = moderate, 3 = severe).

The operation was performed with the patient under general anesthesia and in lithotomy and anti-Trendelenburg (30°–45°) positions, with closed CO₂ pneumoperitoneum. Five trocars (Endopath, Ethicon Endosurgery) were used in all procedures. Patients with transient sliding hernia at radiologic evaluation were treated by standard gastric banding with a 15-ml virtual pouch calibration. In cases of hiatal hernia clearly presenting at radiologic evaluation, patients were planned for dissection of the esophagus and closure of the diaphragmatic crus, followed by positioning of the Lap-Band around the esophagus. Postoperative evaluation was based on clinical evaluation of specific symptoms, weight loss, and complications. Data were expressed as mean ± standard deviation (SD).

Results

From January 1996 to July 1998, 40 patients underwent LASGB: 36 female and 4 male patients, mean age 34.4 ± 11.1 years (range 17–59), mean body mass index (BMI) 44.7 ± 5.8 kg/m² (range 35.8–58.2). Twelve of the 40 (30%) were considered to be affected by GER. The results of esophageal investigation and current BMI for each patient are given in Table 1. The main basal pressure of the LES in GER patients was 11.3 ± 3.8 mm Hg (range 5.5–28). In all but 1 patient (Patient 12, Table 1), the LES was

hypotonic. Four of 12 patients with GER (30%) had radiologic evidence of a hiatal hernia. In only 1 patient (Patient 2, Table 1) having this condition, the esophagus was dissected and the esophageal diaphragmatic crus was closed with a single nonabsorbable stitch using an extracorporeal knot. In the remaining 3 patients, small transient sliding hernias were ignored at surgery, and the standard procedure was performed. The postoperative clinical esophageal symptoms score was negative for all but 1 patient who was lost at follow-up. Two of 12 patients (16.6%) experienced postoperative proximal gastric pouch dilation (Patient 8, Table 1) and band dislocation (Patient 9, Table 1) at 7 months and 4 days, respectively. Both were successfully treated by laparoscopic band repositioning. The results of weight loss in these patients are shown in Figure 1. Comparison of weight loss between the patients with and without GER showed no significant difference.

Discussion

Hiatal hernia has been considered by some to be a contraindication to LASGB. Technically this problem can be resolved by repairing the diaphragmatic crus, reducing the hernia, and closing the defect by interrupted stitches. In the single patient in our series with a 3-year history of GER (LES pressure 11 mm Hg, 100% peristaltic wave with normal amplitude) who required this procedure, the band was

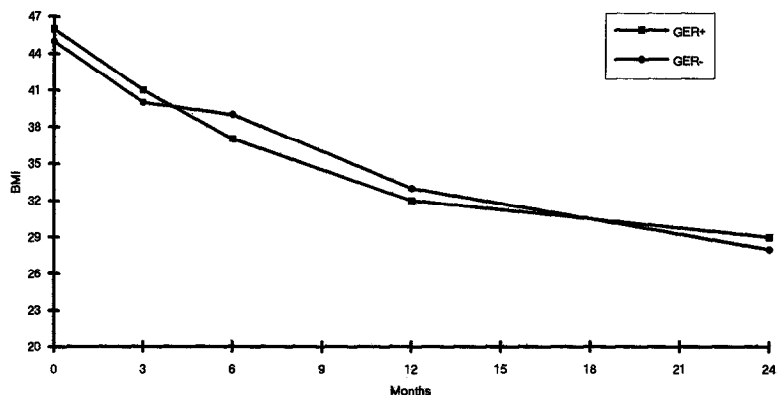


Figure 1. Weight loss in patients with GER.

deliberately positioned around the esophagus, similarly to an Angelchik prosthesis, to create a high-pressure zone above the cardioesophageal junction to reduce GER symptoms. The potential risk of this procedure is the development of esophageal dilation caused by band tightening. Our patient treated by this procedure remains free of GER symptoms, with satisfactory weight loss and without any esophageal dilation, at 2 years follow-up. Patients with esophageal symptoms, positive 24-h pH test results, with or without LES incontinence, and with or without transient small sliding hernia have been treated by the standard laparoscopic banding procedure with a virtual pouch, with optimal results in terms of GER symptoms and weight loss.

In conclusion, hiatal hernia is not a contraindication to LASGB, which is an optimal procedure for obese patients with GER, resolving both the diseases. The use of the Lap-Band to act as an Angelchik

prosthesis requires further confirmation in a larger series.

References

1. Angrisani L, Lorenzo M, Puzziello A, et al. New frontiers in bariatric surgery. Laparoscopic adjustable silicone gastric banding. *Amb Surg* 1997; **4**: 149–51.
2. Angrisani L, Lorenzo M, Esposito G, et al. Laparoscopic adjustable silicone gastric banding: preliminary results of the University of Naples experience. *Obes Surg* 1997; **11**: 268–71.
3. Rosch W. Treatment of non ulcer dyspepsia. *Scand J Gastroenterol* 1987; **22**: 161–4.

(Received September 30, 1998; accepted February 27, 1999)